ResearchGate

See discussions, stats, and author profiles for this publication at: https://www.researchgate.net/publication/350507792

Cryoneurolysis of Innervation to Sacroiliac Joints: Technical Description and Initial Results—A Case Series

Article *in* A & A Practice · March 2021

DOI: 10.1213/XAA.0000000000001427

CITATIONS
0

READS
86

6 authors, including:

Rajendra Sahoo
Kalinga Institute of Medical Sciences
44 PUBLICATIONS **92** CITATIONS

SEE PROFILE

Gautam Das
Daradia: The Pain Clinic, Kolkata, India
129 PUBLICATIONS **132** CITATIONS

SEE PROFILE

Laxmi Pathak
Universal College of Medical Sciences
23 PUBLICATIONS **18** CITATIONS

SEE PROFILE

Debjyoti Dutta
11 PUBLICATIONS **21** CITATIONS

SEE PROFILE

Some of the authors of this publication are also working on these related projects:

Project Fibromyalgia View project

Project LBP in pregnancy View project

All content following this page was uploaded by Anuj Bhatia on 23 April 2021.

The user has requested enhancement of the downloaded file.

Cryoneurolysis of Innervation to Sacroiliac Joints: Technical Description and Initial Results—A Case Series

Rajendra Kumar Sahoo, MBBS, MD, CIPS, ASRA-PMUC, Pain Fellowship (Canada),*
Gautam Das, MD, FIPP,† Laxmi Pathak, MD,† Debjyoti Dutta, MD, FIPP, FIAPM,† Chinmoy Roy, MD, FIPP,† and Anuj Bhatia, MBBS, MD, FRCA, FFPMRCA, FIPP, FRCPC (Anesthesia & Pain Medicine), EDRA, CIPS, ASRA-PMUC‡

The sacroiliac joint (SIJ) is a common source of pain in patients with low back pain. Untreated pain from the SIJ can lead to prolonged discomfort and financial burden. Interventional treatments for SIJ-related pain include intraarticular steroid injection and radiofrequency ablation but both procedures provide pain relief for a limited duration. Cryoneurolysis is another neuroablative technique that is effective in various chronic pain conditions. However, there is no clear description of SIJ cryoneurolysis in the published literature. In this report, we present 5 patients with SIJ-related pain and we describe the ultrasound-guided SIJ cryoneurolysis technique and its analgesic efficacy. (A&A Practice. 2021;15:e01427.)

GLOSSARY

Bil = bilateral; **cryo** = cryoneurolysis; **F** = female; **FL** = fluoroscopy; **LBP** = low back pain; **LSC** = lateral sacral crest; **M** = male; **NRS** = numerical rating scale; **RFA** = radiofrequency ablation; **SD** = standard deviation; **SIJ** = sacroiliac joint; **US** = ultrasound

Downloaded from http://journals.lww.com/aaoa2 by BhDMf5ePHKav1zEoum1tQfN4a+kJLhEZgbsIHo4XMi0hCywCX1AWnYQp/IlQrHD3i3D0OdRyi7TvSFl4Cf3VC4/OAVpDDa8KKGKV0Ymy+78= on 04/08/2021

Low back pain (LBP) is a major health burden and a common reason for accessing health care. Sacroiliac joint (SIJ) pain is a known source of LBP with a prevalence of 15%–30%.[1] SIJ-related pain can lead to chronic LBP with significant discomfort and disability. Injections of local anesthetic and steroid into or around the SIJ provide short- to intermediate-term pain relief. Radiofrequency ablation (RFA) of the SIJ can provide more sustained pain relief, with the literature supporting better pain relief from "cooled" RFA in comparison to conventional RFA.[1–3] However, a recent systematic review found that the pain relief from SIJ RFA is partial and of limited duration.[4,5] Cryoneurolysis is another option for neuroablation that has been studied in various chronic pain conditions with demonstrated benefit.[6–8] However, there are no published clinical reports on efficacy of cryoneurolysis in SIJ-related pain. We describe our technique of ultrasound-guided cryoneurolysis of SIJ and its outcomes in 5 patients with LBP of SIJ origin.

This study was approved by the Institutional Review Board of the Daradia Pain Hospital. Written informed consent was obtained from the 5 patients whose data are included in this report.

From the *Department of Anesthesiology and Pain management, Kalinga Institute of Medical Sciences, Bhubaneswar, India; †Department of Pain Medicine, Daradia Pain Hospital, Kolkata, India; and ‡Department of Anesthesia and Pain Management, University Health Network—Toronto Western Hospital, University of Toronto, Toronto, Ontario.

Accepted for publication February 5, 2021.

Funding: None.

The authors declare no conflicts of interest.

Address correspondence to Rajendra Kumar Sahoo, MBBS, MD, CIPS, ASRA-PMUC, Pain Fellowship (Canada), Department of Anesthesiology and Pain management, Kalinga Institute of Medical Sciences, Bhubaneswar, India. Address e-mail to sss.raaj@gmail.com.

Copyright © 2021 International Anesthesia Research Society.
DOI: 10.1213/XAA.0000000000001427

CASES' DESCRIPTIONS

The 5 patients presented to our tertiary-care pain clinic with chronic axial LBP. All the patients had LBP for over 6 months despite maximal conservative medical management and physiotherapy. The diagnosis of SIJ pain was based on the clinical presentation of pain around the SIJ and positive SIJ provocation tests with or without radiological evidence. All 5 patients underwent diagnostic SIJ intraarticular injections under fluoroscopy guidance. The lower part of the dorsal SIJ was accessed with a 22-gauge spinal needle. Accurate SIJ needle placement was confirmed with intraarticular dye spread with anteroposterior and lateral fluoroscopy, and then, 3-mL 2% lidocaine was injected in the affected SIJ. A reduction in pain of 50% or greater on the numerical rating scale (NRS: 0: no pain, 10: worst pain imaginable) following the diagnostic SIJ injection was considered a positive response.

All 5 patients responded positively to the diagnostic SIJ injection. Seven days later, all 5 patients were offered SIJ cryoneurolysis, because their pain intensity had returned to their baseline levels. The patients were positioned prone with a pillow under their iliac crests. Under strict aseptic precautions, a curvilinear ultrasound probe (2–5 MHz, M Turbo, Sonosite, Gurugram, Haryana, India) was first placed in a longitudinal orientation to identify the first 3 posterior sacral foramina on the planned interventional side (Figure 1A). The probe was then moved laterally to identify the lateral sacral crest (LSC) where the lateral branches of the first, second, and third sacral nerves confluence to innervate the posterior SIJ (Figure 1B). The intended cryoprobe skin entry point and deeper paraspinal musculature were infiltrated with 5-mL 1% lidocaine and then a stab incision was made with a size 11 blade. Under ultrasound-guidance, a 14Fr cryoprobe (Metrum Cryoflex, Warsaw, Poland) was inserted through the skin and directed through the parasacral muscles until the bone was contacted at the LSC just lateral to the S3 foramen (Figure 2A). The probe was advanced further in a cranial

Copyright © 2021 International Anesthesia Research Society. Unauthorized reproduction of this article is prohibited.

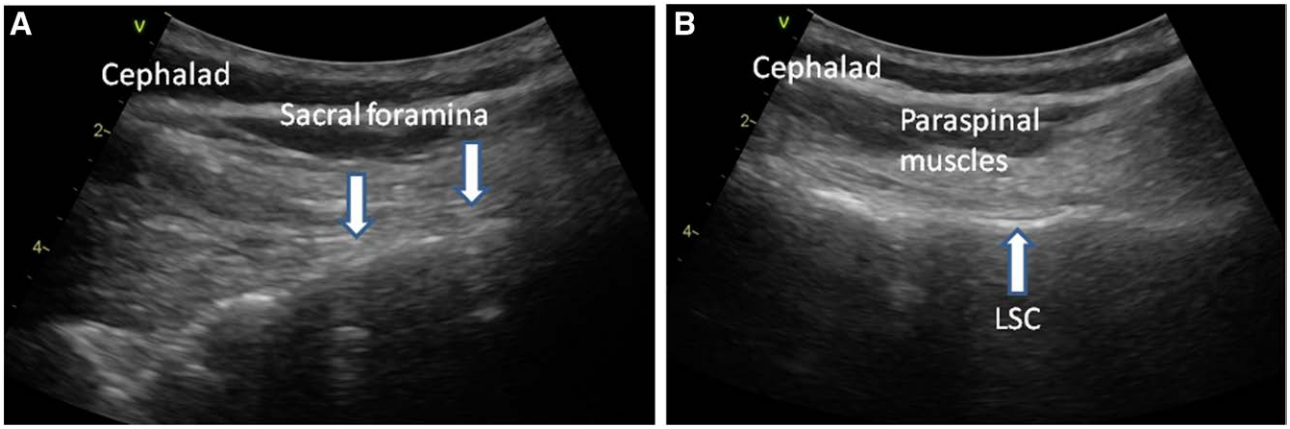

Figure 1. Sonoanatomy for cryoprobe insertion. A, Longitudinal sonoanatomy view showing the sacral foramina (highlighted with white bold arrows). B, Longitudinal sonoanatomy view just lateral to sacral foramina for cryoneurolysis of the SIJ. LSC indicates lateral sacral crest; SIJ, sacroiliac joint.

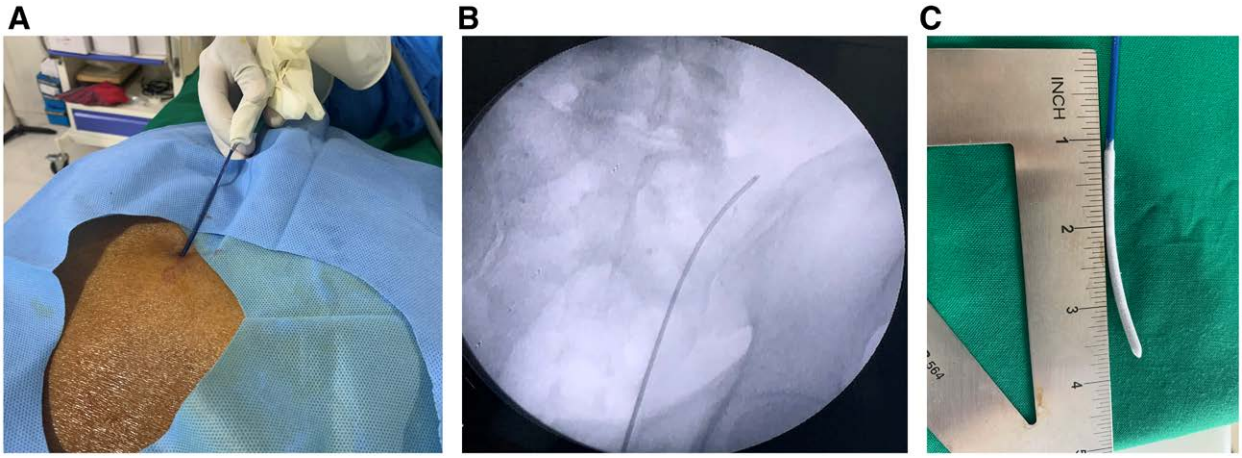

Figure 2. Cryoprobe for cryoneurolysis of the sacroiliac joints. A, Single-entry insertion of cryoprobe. B, Fluoroscopy image showing cryoprobe position along the lateral sacral crest. C, Cryoprobe at the end of cryoneurolysis.

direction so that it remained in contact with the bone over the lateral crest to target the lateral branches of S1-S3. The final cryoprobe position was confirmed with fluoroscopy using anteroposterior (Figure 2B) and lateral views to ensure that the probe was lateral to the posterior sacral foramina and close to the posterior surface of the sacrum. Before proceeding to cryoneurolysis, sensory stimulation at 50 Hz was applied through the cryoprobe to stimulate the targeted nerves resulting in paresthesias concordant with the patients' reported location of pain. Motor stimulation at 2 Hz did not produce muscle contraction in the myotomes innervated by the first 3 ventral sacral nerve roots. The cryoneurolysis machine was connected to a CO_2/N_2O cylinder. A 3-minute freezing cycle (−78 °C for CO_2 and −88 °C for N_2O) and a 1-minute defrosting cycle was initiated. Freezing and defrosting was visualized under ultrasound. To increase the surface area of neurolysis, the probe was moved cephalad or caudad depending on the position of the probe with respect to the LSC and the probability of freezing the L5 dorsal ramus. A second cycle of freezing and defrosting was then performed (Figure 2C). After defrosting was completed, the probe was removed and the skin was covered with adhesive tape. All patients were assessed for the degree of pain relief at the end of the procedure.

Table 1. Patient Characteristics

Patients	Age (y)	Sex	Laterality	Duration of pain (mo)
1	61	F	Bil	16
2	69	M	Left	36
3	43	M	Bil	12
4	77	M	Right	48
5	34	M	Bil	24

Abbreviations: Bil, bilateral; F, female; M, male.

RESULTS

The demographic data of the 5 patients are reported in Table 1. All 5 patients with chronic LBP responded positively to the diagnostic SIJ intraarticular injections (Table 2). Postcryoneurolysis outcome data were collected over the phone because of restrictions on in-person visits during the coronavirus pandemic. Immediately following the cryoneurolysis, all 5 patients reported excellent pain relief (Table 2). Three patients reported no pain at 1-month follow-up, whereas 2 patients described their NRS pain score as 1 on a scale of 0–0. Furthermore, at follow-up at 3 and 6 months, all patients reported excellent (>50%) pain relief (Table 2). Two of the 5 patients reported moderate-intensity pain around the injection area, which lasted for 3–4 days and responded

Copyright © 2021 International Anesthesia Research Society. Unauthorized reproduction of this article is prohibited.

Table 2. NRS Pain Score at Baseline and Postprocedure

Patients	Baseline NRS pain score on a 0–10 scale	Percentage reduction in NRS following SIJ diagnostic block	Percentage reduction in NRS immediately after cryo	NRS at 1 mo following SIJ cryo	NRS at 3 mo following SIJ cryo	NRS at 6 mo following SIJ cryo
1	8	60–70	70–80	0	2	2
2	6	60	70–80	0	1	2
3	8	70	100	0	0	0
4	8	60–70	80	1	1	2
5	7	80	80–90	1	2	2

Abbreviations: Cryo, cryoneurolysis; NRS, Numerical Rating Scale; SIJ, sacroiliac joint.

Table 3. A Comparison of Different Modalities for Denervating the Sacroiliac Joint

Parameters	Conventional RFA (strip lesion)	Cooled RFA	Cryoneurolysis
Time required to perform the procedure, min (mean ± SD)	19.4 ± 8.2	48.8 ± 9.6	12.6 ± 1.5
Imaging modality	FL	FL	US ± FL
Patients reporting ≥50% reduction in pain scores at 6 mo	81%	91%	100%
Cost	Moderate	High	Moderate
Discomfort to patient	Mild to moderate	Moderate to severe	Mild to moderate

Data on conventional (strip lesion) and cooled RFA are from published literature[12] and data for cryoneurolysis are from the data reported in this article.
Abbreviations: FL, fluoroscopy; RFA, radiofrequency ablation; SD, standard deviation; US, ultrasound.

to ice application and anti-inflammatory medications. None of the patients were taking oral analgesics for SIJ pain at follow-up 6 months after the procedure. No complications were noted in any of the patients.

DISCUSSION

We report the analgesic benefits in 5 patients who underwent cryoneurolysis of the nerve supply to their SIJ. Published literature suggests that cryoneurolysis can be effective for facet-mediated pain, intercostal neuralgia, neuropathic pain, knee osteoarthritis, phantom limb pain, and other chronic pain syndromes.[6–10]

SIJ pain is a challenging pain syndrome and difficult to manage with currently available treatment modalities.[1] The complex innervation of the SIJ makes it difficult to completely denervate the joint and this may explain the short-lasting pain relief from various RFA techniques. The published literature suggests better and long-lasting pain relief with cooled as compared to conventional RFA. A recent descriptive review evaluated the safety and efficacy of cooled RFA in SIJ pain. It included 7 studies (4 retrospective studies, 2 randomized trials, and 1 prospective observational study) and the results demonstrated that pain intensity decreased significantly after cooled RFA compared with pretreatment NRS. The mean difference in NRS pain scores (scale 0–10) was 3.81. Seventy-two percent of the patients reported analgesic benefit as measured by the Global Perceived Effect. Only mild complications were observed in the 7 studies, including transient hip pain, soreness, and numbness.[11] A trial that compared analgesic outcomes at 6 and 12 months after the procedures reported better analgesic results with cooled as compared to conventional RFA (strip lesion using the Simplicity III [NeuroTherm, Inc, Wilmington, MA]) of the SIJ.[12] Though a meta-analysis on outcomes of RFA treatments for SIJ pain reported significantly lower pain scores with cooled as compared to thermal RFA at 1-month follow-up, the efficacy of the 2 techniques was similar at 6- and 12-month follow-up visits.[13] We have provided a comparison of results of these 2 modalities and cryoneurolysis for denervating the SIJ in Table 3.

The term "posterior sacral network" has been proposed to describe the conglomeration of nerves that innervate the posterior SIJ.[13] The lateral branches of the first 3 sacral nerve roots contribute to innervation of the SIJ and these branches can be reliably accessed at the LSC. This anatomical feature provides the rationale to perform ultrasound-guided sacral lateral branch block and LSC RFA.[14,15] We applied these principles to perform cryoneurolysis of innervation to the SIJ. The ultrasound-assisted technique has the potential to reduce and perhaps eliminate radiation exposure from fluoroscopy, because cryoprobe positioning can be accomplished using ultrasound while it can sometimes be difficult to identify sacral foramina with fluoroscopy.[2] However, comparative trials are required to evaluate the impact of different imaging modalities (or a combination thereof) for performing SIJ cryoneurolysis.

There are several other advantages for our cryoneurolysis technique including ablation of the posterior sacral network using a single skin entry point for the probe and short procedure time. Cooled RFA of the SIJ involves at least 8 large bore RFA cannulas placement and some physicians may add RFA cannulas for L5 dorsal ramus or the S4 lateral branch. The cost can be another limiting factor for cooled RFA, because specialized equipment (a rotor pump to circulate fluids) to ensure cooling of the RFA probe is required. Postprocedure tingling and numbness have been reported in up to 20% of individuals after SIJ RFA, whereas such complications are uncommon after cryoneurolysis.[1] No complications were observed in our case series. However, neuroma formation or increased pain at 8 weeks after intercostal nerve cryoneurolysis that usually resolves spontaneously has been reported.[6]

There are some limitations in our research report, such as a small sample size, absence of blinding, and a lack of comparator groups. We were also unable to collect data on functional recovery based on validated tools. We intend to conduct an adequately powered randomized controlled trial with blinding of observers that compare cryoneurolysis against RFA for denervating the SIJ. Our results,

Copyright © 2021 International Anesthesia Research Society. Unauthorized reproduction of this article is prohibited.

the widespread availability of ultrasound, and the lack of complexity of our proposed technique should spur further research on this modality.

DISCLOSURES

Name: Rajendra Kumar Sahoo, MBBS, MD, CIPS, ASRA-PMUC, Pain Fellowship (Canada).
Contribution: This author helped concept, design the study, review the literature, and prepare the manuscript.
Name: Gautam Das, MD, FIPP.
Contribution: This author helped concept, design the study, review the manuscript, and perform the procedures.
Name: Laxmi Pathak, MD.
Contribution: This author helped review the literature, and review and prepare the manuscript.
Name: Debjyoti Dutta, MD, FIPP, FIAPM.
Contribution: This author helped review the literature, and review and edit the manuscript.
Name: Chinmoy Roy, MD, FIPP.
Contribution: This author helped review the literature, and review and edit the manuscript.
Name: Anuj Bhatia, MBBS, MD, FRCA, FFPMRCA, FIPP, FRCPC (Anesthesia & Pain Medicine), EDRA, CIPS, ASRA-PMUC.
Contribution: This author helped in critical review of the literature, editing and preparation of the manuscript.
This manuscript was handled by: BobbieJean Sweitzer, MD, FACP.

REFERENCES

1. Cohen SP, Chen Y, Neufeld NJ. Sacroiliac joint pain: a comprehensive review of epidemiology, diagnosis and treatment. *Expert Rev Neurother*. 2013;13:99–116.
2. Kapural L, Nageeb F, Kapural M, Cata JP, Narouze S, Mekhail N. Cooled radiofrequency system for the treatment of chronic pain from sacroiliitis: the first case-series. *Pain Pract*. 2008;8:348–354.
3. Patel N, Gross A, Brown L, Gekht G. A randomized, placebo-controlled study to assess the efficacy of lateral branch neurotomy for chronic sacroiliac joint pain. *Pain Med*. 2012;13:383–398.
4. King W, Ahmed SU, Baisden J, et al. Diagnosis and treatment of posterior sacroiliac complex pain: a systematic review with comprehensive analysis of the published data. *Pain Med*. 2015;16:257–265.
5. Huygen F, Kallewaard JW, van Tulder M, et al. "Evidence-based interventional pain medicine according to clinical diagnoses". Update 2018. *Pain Pract*. 2019:19:664–675.
6. Trescot AM. Cryoanalgesia in interventional pain management. *Pain Physician*. 2003;6:345–360.
7. Manuel Cunha E Sa, Behari S. Cryoneurolysis for the treatment of lumbar zygoapophyseal joint pain. *Acta Neurochir*. 2011;153:1021–1022.
8. Wolter T, Kleinmann B, Knoeller S. Cryoneurolysis for the treatment of cervical facet joint syndrome: a technical note. *J Pain Res*. 2018;11:1165–1169.
9. Zakrzewska JM, Nally FF. The role of cryotherapy (cryoanalgesia) in the management of paroxysmal trigeminal neuralgia: a six year experience. *Br J Oral Maxillofac Surg*. 1988;26:18–25.
10. Radnovich R, Scott D, Patel AT, et al. Cryoneurolysis to treat the pain and symptoms of knee osteoarthritis: a multicenter, randomized, double-blind, sham-controlled trial. *Osteoarthritis Cartilage*. 2017;25:1247–1256.
11. Shih CL, Shen PC, Lu CC, et al. A comparison of efficacy among different radiofrequency ablation techniques for the treatment of lumbar facet joint and sacroiliac joint pain: a systematic review and meta-analysis. *Clin Neurol Neurosurg*. 2020;195:105854.
12. Tinnirello A, Barbieri S, Todeschini M, Marchesini M. Conventional (simplicity III) and cooled (SInergy) radiofrequency for sacroiliac joint denervation: one-year retrospective study comparing two devices. *Pain Med*. 2017;18:1731–1744.
13. Sun HH, Zhuang SY, Hong X, Xie XH, Zhu L, Wu XT. The efficacy and safety of using cooled radiofrequency in treating chronic sacroiliac joint pain: a PRISMA-compliant meta-analysis. *Medicine (Baltimore)*. 2018;97:e9809.
14. Roberts SL, Burnham RS, Ravichandiran K, Agur AM, Loh EY. Cadaveric study of sacroiliac joint innervation: implications for diagnostic blocks and radiofrequency ablation. *Reg Anesth Pain Med*. 2014;39:456–464.
15. Roberts SL, Burnham RS, Agur AM, Loh EY. A cadaveric study evaluating the feasibility of an ultrasound-guided diagnostic block and radiofrequency ablation technique for sacroiliac joint pain. *Reg Anesth Pain Med*. 2017;42:69–74.

Copyright © 2021 International Anesthesia Research Society. Unauthorized reproduction of this article is prohibited.
View publication stats